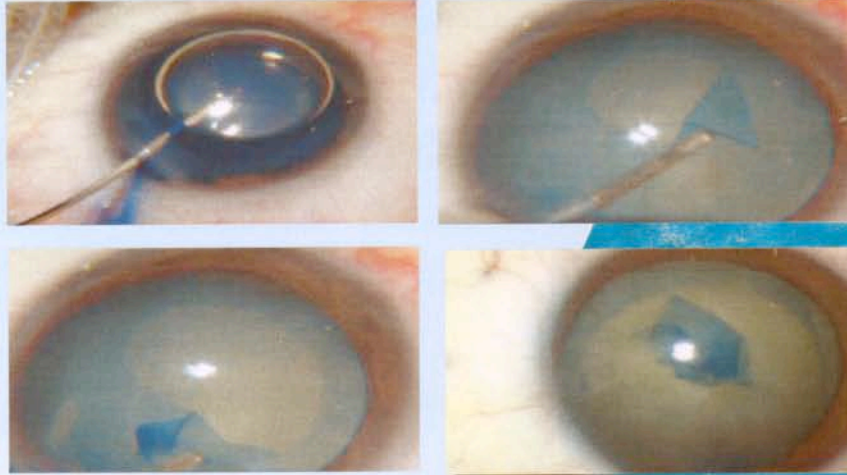


BCC

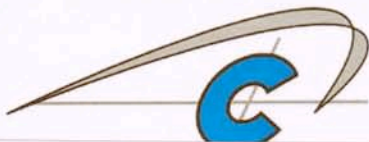
Blue Color Caps

Intraoperative views of capsulorhexis after BCC staining of the anterior capsule in an eye with a mature cataract. The BCC can be easily distinguished from the underlying gray lenticular tissue.



(Photographs by courtesy of Dr HUET and Dr REDOR)

CE
N° 0459



VISION
matrix

31 East Parade
Harrogate
HG1 5LQ
Tel: 01423-705058
Fax: 01423-705056

BCC

Blue Color Caps

Staining Solution for Cataract Surgery
Anfarbelosung für die Kataraktchirurgie

Solution Colorante pour la Chirurgie de la Cataracte
Solución Tintada para Cirugía de Cataratas

